



The Brazilian Journal of INFECTIOUS DISEASES

www.elsevier.com/locate/bjid



Clinical image

Pulmonary involvement in patients with measles



Bruno Hochhegger ^a, Gláucia Zanetti ^b, Edson Marchiori ^{b,*}

^a Pontifícia Universidade Católica do Rio Grande do Sul, Programa de Pós-Graduação em Medicina, Porto Alegre, RS, Brazil

^b Universidade Federal do Rio de Janeiro, Rio de Janeiro, RJ, Brazil

ARTICLE INFO

Article history:

Received 17 February 2020

Accepted 21 March 2020

Available online 10 April 2020

A 55-year-old male presented with a 4-day history of fever, cough, and coryza. One day later, a maculopapular rash appeared, primarily on the face and subsequently spreading. He sought medical attention and was admitted for investigation. At that time, Koplik's spots were also identified. Computed tomography of the chest showed consolidations and ground-glass opacities in both lungs (Fig. 1). A diagnosis of measles was made after measles virus-specific immunoglobulin M antibodies were detected in serum and the virus was detected by real-time polymerase chain reaction. The patient improved and was discharged on the sixth day after admission.

In recent years, there have been several measles outbreaks, not only in children but also in adults, with serious and occasionally fatal complications. Many countries are in the midst of major outbreaks of the disease, all regions of the world experiencing an increase in the number of cases. In 2019, approximately 61,000 suspected cases of measles were

reported in Brazil, approximately 16,000 of which were confirmed, either by laboratory tests or on the basis of clinical and epidemiological criteria. Most of the cases occurred in the states of São Paulo, Minas Gerais, Paraná, Pernambuco, and Rio de Janeiro.¹

Most measles-related deaths are due to complications. Common complications include pneumonia, severe diarrhea, otitis, and keratoconjunctivitis, which is a leading cause of blindness. Complications of measles are more common in children under five years of age who are malnourished, in adults over 20 years of age, in pregnant women, and in immunocompromised individuals. Pneumonia is a major cause of morbidity and mortality in measles patients, being caused by the virus itself or by secondary bacterial infection.^{2,3} The imaging findings are nonspecific, potentially including consolidations or ground-glass opacities with a lobular or segmental distribution, thickening of the bronchial/bronchiolar walls, nodules, and small centrilobular nodules.⁴

* Corresponding author.

E-mail address: edmarchiori@gmail.com (E. Marchiori).

<https://doi.org/10.1016/j.bjid.2020.03.004>

1413-8670/© 2020 Sociedade Brasileira de Infectologia. Published by Elsevier España, S.L.U. This is an open access article under the CC BY-NC-ND license (<http://creativecommons.org/licenses/by-nc-nd/4.0/>).

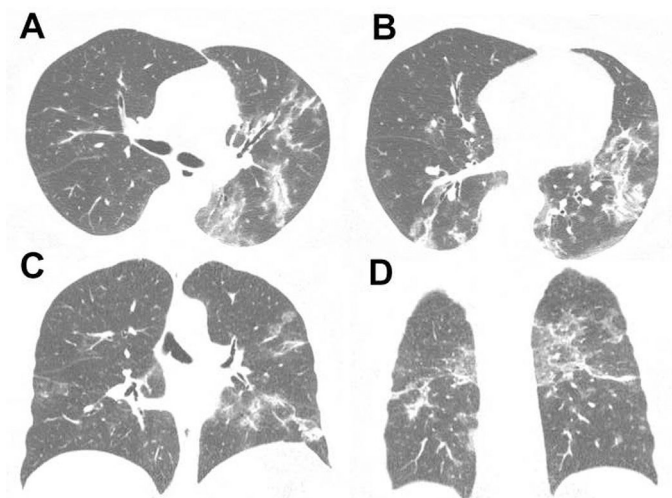


Fig. 1 – Computed tomography of the chest. Axial slices (A and B) and coronal slices (C and D) showing multiple foci of consolidation and ground-glass opacities in both lungs. There is no evidence of lymph node enlargement or pleural effusion.

Conflict of interest

The authors declare no conflicts of interest.

REFERENCES

1. Boletim Epidemiológico. Secretaria de Vigilância em Saúde | Ministério da Saúde. 2019;50. Available from: www.saude.gov.br/svs [accessed 24.1.20].
2. Strebel PM, Orenstein WA. Measles. *N Engl J Med*. 2019;381:349–57.
3. Moss WJ. Measles. *Lancet*. 2017;390:2490–502.
4. Albarello F, Cristofaro M, Busi Rizzi E, Giancola ML, Nicastrì E, Schininà V. Pulmonary measles disease: old and new imaging tools. *Radiol Med*. 2018;123:935–43.