



The Brazilian Journal of INFECTIOUS DISEASES

www.elsevier.com/locate/bjid



Clinical image

Novel coronavirus pneumonia

Na Wu, Yi Zhang*, Yong-Sheng Yu *

Shanghai Jiao Tong University Affiliated Sixth People's Hospital, Department of Infectious Diseases, Shanghai, China



ARTICLE INFO

Article history:

Received 17 February 2020

Accepted 9 March 2020

Available online 20 March 2020

A previously healthy 64-year-old female was admitted to our hospital with a two-day history of high fever, fatigue, and dry cough. She had a history of recent travel from Wuhan, China, the center of an outbreak of 2019 novel coronavirus (2019-nCoV), to Shanghai one day before admission. On physical

examination, she was febrile and tachypneic. Coarse breath sounds in both lungs were heard during inspiration and expiration. Laboratory data showed a white blood cell (WBC) count of $4.6 \times 10^9/L$ with 87.4% neutrophils and 10.0% lymphocytes. Inflammatory marker levels were elevated with erythrocyte

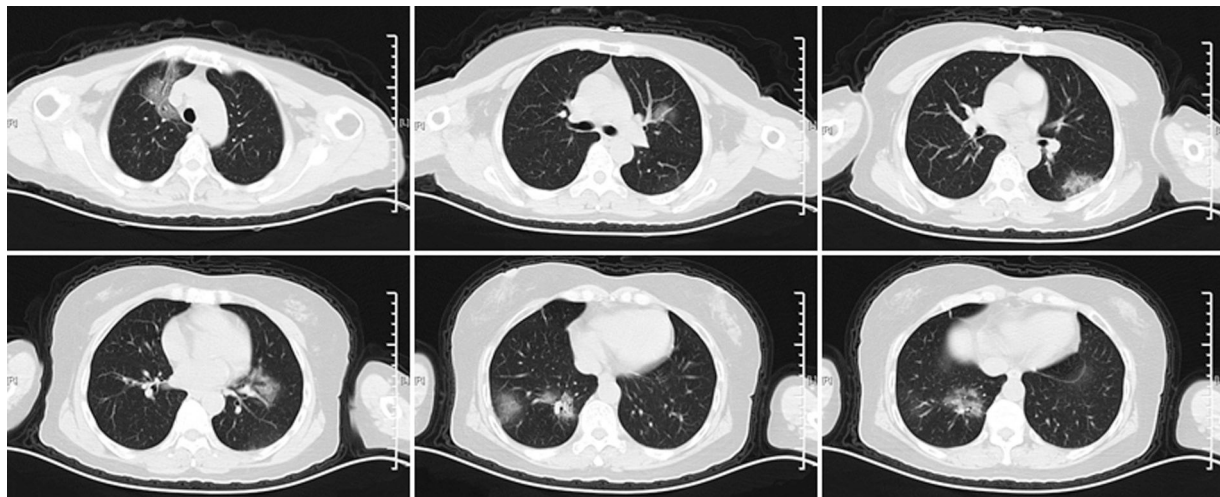


Fig. 1 – Computed tomography (CT) scan of the chest showing bilateral multifocal ground-glass opacities on day 2 after the onset of illness.

* Corresponding authors.

E-mail addresses: zhangyi198068@163.com (Y. Zhang), yuyongshengsy@163.com (Y. Yu).

<https://doi.org/10.1016/j.bjid.2020.03.001>

1413-8670/© 2020 Sociedade Brasileira de Infectologia. Published by Elsevier España, S.L.U. This is an open access article under the CC BY-NC-ND license (<http://creativecommons.org/licenses/by-nc-nd/4.0/>).

sedimentation rate (ESR) of 67 mm/h and C-reactive protein (CRP) of 57.7 mg/L. A computed tomography (CT) scan of the chest showed multiple ground-glass opacities in both lungs (Fig. 1). Real-time reverse transcription-polymerase (RT-PCR) chain reaction assay of the specimen collected from the patient's throat was positive for the 2019-nCoV nucleic acid. Subsequently, the patient was transferred to Shanghai Public Health Clinical Center (SHPHCC), the designated hospital, for further treatment. She had a satisfactory response to the medical treatment and was discharged upon recovery two weeks after the onset of illness.

The common symptoms at onset of novel coronavirus pneumonia (NCP) are fever, fatigue, dry cough, myalgia, and dyspnea.¹ However, a significant part of NCP patients initially present with diarrhea and nausea prior to the development of fever and dyspnea.¹ The typical findings of chest CT scans include bilateral ground-glass and consolidative opacities.¹⁻⁴ Additional features, such as nodular, reticular, peripheral opacities and crazy-paving patterns may be helpful in early diagnosis.⁴ Importantly, early diagnosis is beneficial to the patients and the public health surveillance and response systems.

Conflicts of interest

The authors declare no conflicts of interest.

Acknowledgements

This work was partly supported by the Medical Education Research Project of Shanghai Jiao Tong University School of Medicine (No. YB150712).

REFERENCES

1. Wang D, Hu B, Hu C, et al. Clinical Characteristics of 138 Hospitalized Patients with 2019 Novel Coronavirus-Infected Pneumonia in Wuhan, China. *JAMA*. 2020;323:1061-9.
2. Huang C, Wang Y, Li X, et al. Clinical features of patients infected with 2019 novel coronavirus in Wuhan, China. *Lancet*. 2020;395:497-506.
3. Chen N, Zhou M, Dong X, et al. Epidemiological and clinical characteristics of 99 cases of 2019 novel coronavirus pneumonia in Wuhan, China: a descriptive study. *Lancet*. 2020;395:507-13.
4. Chung M, Bernheim A, Mei X, et al. CT Imaging Features of 2019 Novel Coronavirus (2019-nCoV). *Radiology*. 2020;295:202-7.