



The Brazilian Journal of INFECTIOUS DISEASES

www.elsevier.com/locate/bjid



Case report

Unusual oral findings of the toxic epidermal necrolysis in an HIV-infected patient: a case report



Vinicius da Costa Vieira ^{a,1}, Viviane Almeida Sarmiento ^{b,1},
Patricia Miranda Leite Ribeiro ^b, Eduardo Martins Netto ^c, Carlos Brites ^c,
Liliane Lins-Kusterer ^{c,*}

^a Complexo Hospitalar Universitário Professor Edgard Santos, Serviço de Estomatologia, Salvador, BA, Brazil

^b Universidade Federal da Bahia, School of Dentistry, Salvador, BA, Brazil

^c Complexo Hospitalar Universitário Professor Edgard Santos, Laboratório de Investigação de Doenças Infecciosas, Salvador, BA, Brazil

ARTICLE INFO

Article history:

Received 18 April 2019

Accepted 16 August 2019

Available online 25 September 2019

Keywords:

Toxic epidermal necrolysis
Stevens–Johnson syndrome
Antiretroviral therapy
HIV.

ABSTRACT

Erythema multiforme (EM), Stevens-Johnson Syndrome and Toxic Epidermal Necrolysis (TEN) have been reported as possible adverse effects of some classes of first-line antiretroviral drugs (ART) for HIV treatment. Herein we report an unusual presentation of TEN lesions associated with ART in an HIV-infected patient. The patient presented disseminated cutaneous eruption and oral lesions from the lips to the oropharynx region, causing odynophagia and dysphagia. In the tongue, circular, atypical erythematous lesions appeared, increasing in diameter over seven days and coalescing since then to complete remission. TEN treatment included efavirenz interruption, use of methylprednisolone, prophylactic antibiotic, and daily laser therapy with low-intensity red light. The circular oral lesions have not been described yet. Reporting our findings and clinical management may help diagnosing other similar cases and guide the clinical conduct. Analgesia and acceleration of oral ulcer repair with red laser therapy are recommended.

© 2019 Sociedade Brasileira de Infectologia. Published by Elsevier España, S.L.U. This is an open access article under the CC BY-NC-ND license (<http://creativecommons.org/licenses/by-nc-nd/4.0/>).

Introduction

The aim of antiretroviral therapy (ART) is to suppress plasma HIV replication, restore and preserve immunologic function reducing HIV-associated morbidity, extending the duration

and quality of survival, and preventing HIV transmission.¹ Most current recommendations indicate early ART initiation regardless of CD4+ T lymphocyte cell count.^{1–3}

The most used first-line ART regimens are combinations of three different antiretroviral drugs, including two nucleoside reverse transcriptase inhibitors plus one of the

* Corresponding author at: Laboratório de Pesquisa em Infectologia - Research Laboratory of Infectious Diseases, Edgard Santos Federal University Hospital, Federal University of Bahia, Rua Augusto Viana, S/n, Canela, Salvador, Bahia, CEP-40110060, Brazil.

E-mail addresses: viniciusvieiraoh@hotmail.com (V. da Costa Vieira), viviane.sarmiento@gmail.com (V. Almeida Sarmiento), nettoeduardom@hotmail.com (E. Martins Netto), crbrites@gmail.com (C. Brites), liliane.lins@ufba.br (L. Lins-Kusterer).

¹ These authors have equally contributed for this work.

<https://doi.org/10.1016/j.bjid.2019.08.003>

1413-8670/© 2019 Sociedade Brasileira de Infectologia. Published by Elsevier España, S.L.U. This is an open access article under the CC BY-NC-ND license (<http://creativecommons.org/licenses/by-nc-nd/4.0/>).

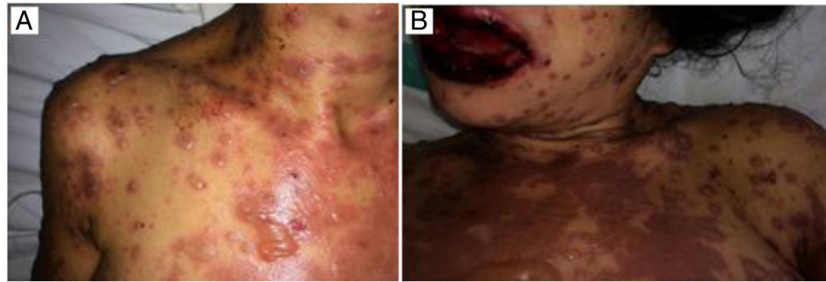

Fig. 1 – Cutaneous lesions at hospital admission (a) and during treatment (b), revealing epidermis detachment from the underlying dermis, leading to bullae.

following: integrase inhibitor, non-nucleoside reverse transcriptase inhibitor, or protease inhibitor with a pharmacokinetic enhancer.^{1,2}

The Brazilian Ministry of Health recommends two nucleoside reverse transcriptase inhibitors plus an integrase inhibitor.³ Some non-nucleoside reverse transcriptase inhibitors, such as efavirenz (EFV) or nevirapine (NVP),⁴⁻⁸ or even nucleoside reverse transcriptase inhibitors, such as emtricitabine and lamivudine,⁹ have been associated with immune-mediated dermatological reactions such as erythema multiforme (EM), Stevens–Johnson syndrome (SJS) and toxic epidermal necrolysis (TEN). These reactions are characterized by extensive areas of skin scaling, affect multiple organs and systems, and could potentially have fatal outcomes.

SJS, overlap SJS/TEN and TEN are usually drug-induced pathologies.¹⁰ The usual distribution of body surface area detachment in EM is below 10%, presenting localized typical or atypical targets, while SJS involves the body surface area detachment below 10% with widespread erythematous, purpuric macules or flat atypical targets. In overlap SJS/TEN, the body surface area detachment is between 10% and 30%, presenting widespread purpuric macules or flat atypical targets.¹⁰ EM skin lesions are commonly described as “target”.¹¹⁻¹³ SJS/TEN may present mucous membranes involvement, with erythematous, bleeding, painful erosions on the oral mucosa and lips, which can also be found on ocular and anogenital mucosa.^{14,15} Treatment of these conditions, although controversial, usually involves the disease-triggering drug interruption and management of the bare skin areas, infection prevention and minimization of pain.^{15,16} Oral lesions usually disappear slowly, but the use of laser therapy can accelerate tissue recovery and provide fast analgesia.¹⁷

This report describes a clinical case of TEN in an HIV-infected patient who developed TEN, with unusual severe oral lesions after efavirenz use, and a treatment based on low intensity red laser photobiomodulation. The reported case was approved by the Ethical Review Board, Edgard Santos University Hospital (protocol number 1740483). The patient signed an informed consent form.

Case report

MCN, a 35-year-old female, diagnosed with AIDS in 2012, was on Tenofovir, Lamivudine, Atazanavir/ritonavir since

diagnosis. In June 2016, the patient was hospitalized due to pericardial effusion secondary to pulmonary tuberculosis, which was treated with surgical drainage and standard tuberculosis therapy (rifampicin, isoniazid, pyrazinamide, and ethambutol). At that time, the patient had undetectable HIV RNA level and CD4 count of 177 cells/ml. In January 2017, after treatment failure, ART was changed to Tenofovir, Lamivudine and Efavirenz. Eight days after ART switch, she presented fever, erythematous spots, papules and pruritic bullous lesions all over the body (Fig. 1). The patient developed ocular hypersecretion, conjunctivitis, reduced vision, odynophagia and swallowing pain. She was then admitted to Federal University of Bahia Hospital, Salvador, Bahia, Brazil.

At hospital admission, the patient presented regular clinical conditions, without fever or respiratory distress. She was still on rifampicin 150 mg, isoniazid 75 mg, pyrazinamide 400 mg, and ethambutol 275 mg. The suspected diagnosis was TEN secondary to Efavirenz use. ART and anti-tuberculosis treatment were discontinued and intravenous (IV) therapy with Methylprednisolone 40 mg/day was administered. On the following days, she developed tachycardia, fever, difficulty in opening the eyes and dysuria. The patient was placed on isolation precautions to prevent secondary infection. Prophylaxis with sulfamethoxazole 800 mg/trimethoprim 160 mg was started. Methylprednisolone 40 mg/day was tapered off to 10 mg/day within four weeks when it was replaced by oral prednisone 5 mg daily. For the ocular lesions, the patient used ofloxacin 3 mg/ml and dexamethasone 1 mg/ml eye drops and irrigation with 0.9% saline solution. The patient presented pyuria, associated with suprapubic pain and was treated with Imipenem 500 mg/Cilastatin 500 mg for seven days due to the isolation of an ESBL-producer *E. coli* in urine culture.

The oral lesions spread from the lips to the oropharynx region within two days, causing pain and incapacity to ingest solids. On the lips, hemorrhagic lesions formed crusts (Fig. 2). Some circular, atypical erythematous lesions appeared in the tongue, increasing in diameter over the following seven days and coalescing at the end (Fig. 3). Daily low-intensity red laser (5J/cm²) therapy for two weeks was applied in addition to mouthwash with non-alcoholic chlorhexidine (0.12%) twice a day and lips hydration until remission of oral lesions. The patient was discharged after 30 days of hospital admission, with complete healing of cutaneous and mucosal lesions (Fig. 4). ART (atazanavir, ritonavir, lamivudine, tenofovir) was resumed, and the patient was kept on sulfamethoxazole (800 mg)/trimethoprim (160 mg) and oral prednisone (5 mg).

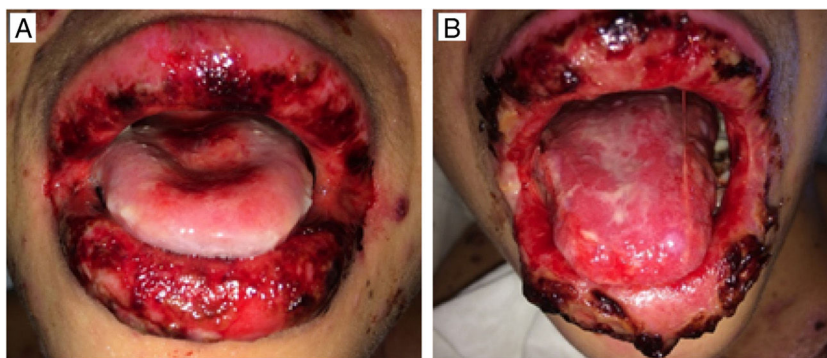


Fig. 2 – (a, b) Erythematous, hemorrhagic, painful erosions of the oral mucosa and lips at different moments.

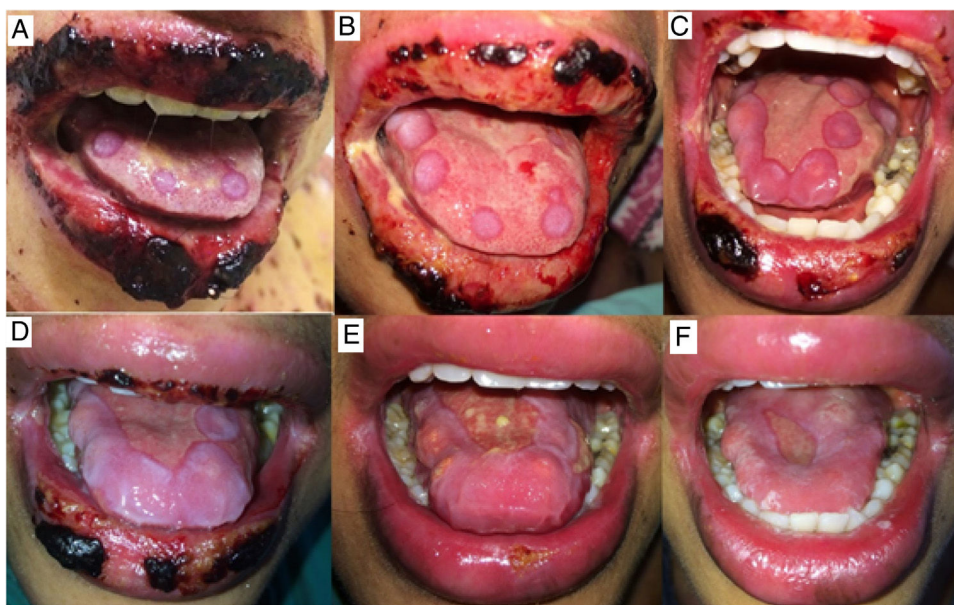

Fig. 3 – (a-f). Concentric, round, erythematous and well-limited erosions on tongue surface (a, b), that increased in size and coalesced (c-e) until remission (f).

Discussion

A retrospective review of patients hospitalized in the dermatology ward from 1992 to 2012 showed that SJS and TEN were the major cause of hospitalization. Sixty-three percent of these patients were HIV-infected, evidencing the susceptibility of this population to adverse reactions.¹⁸ Inappropriate or unnecessary use of drugs like trimethoprim-sulfamethoxazole, atovaquone, clindamycin, and fluconazole, in HIV-infected patients may cause severe adverse drug reactions.¹⁹

Some studies have shown that SJS and TEN may also result from exposure to drugs used in ART regimens, such as efavirenz and nevirapine.^{4,5} Reddy et al.⁴ reported nine cases of SJS and one of TEN associated with the use of nevirapine in patients living with HIV/Aids. A case report has also associated higher doses of nevirapine with SJS in a patient who was using no other medication, had undetectable viral load and a CD4 count higher than 350 cells/ml. The patient tried

to compensate a missing dose of his ART regimen (nevirapine, tenofovir and lamivudine) by doubling the regular dose for two days.⁵ Nevirapine toxicity has been associated with high CD4 counts, undetectable viral load and high plasma drug level. Authors postulate that the sudden increase of plasma levels of nevirapine, in a patient on those conditions, has triggered SJS. In 2016, a case of fatal nevirapine-induced TEN in an HIV-infected patient has been reported.⁶ This association was made based on temporal relationship between drug use the hypersensitivity reaction, and associated clinical signs and symptoms.

In a case-control study,⁷ nevirapine exposure was strongly associated with SJS or TEN in HIV-infected patients, but no association was found with efavirenz, which has been associated with a lower frequency of severe hypersensitivity events when compared to nevirapine.⁸

Another report describes a clinical picture similar to the present case, in which the development of dermatological lesions occurred two weeks after the introduction of efavirenz (600 mg once daily).¹⁵ In the present case, the symptoms

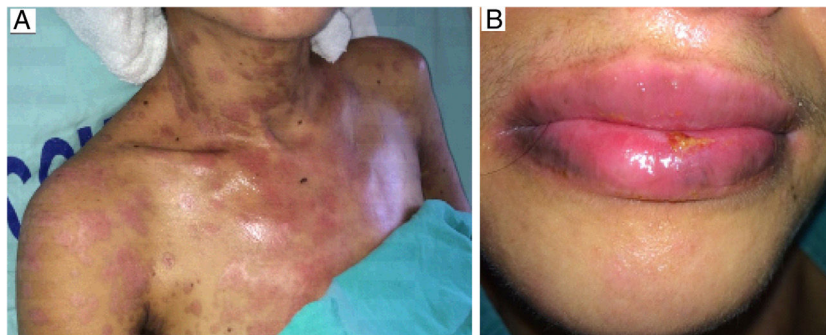


Fig. 4 – (a, b) Remission of dermal lesions (a) and of mouth mucosa (b).

started one week after efavirenz introduction. The causality assessment showed strong clinical correlation between efavirenz use and the onset of dermatological lesions. In both cases, anti-tuberculosis drugs and other ART drugs were already in use and well tolerated. This fact reinforces that those drugs were likely not implicated in disease causality.

Early recognition of the drug reaction and discontinuation of the presumptive drug are very important in SJS management, as well as supportive care provision.¹⁵ Corticosteroids are effective in the initial phase, but they may result in increased risk of infection and delayed wound healing, particularly during the bullous eruption or mucosal erosion.¹⁵ Administration of short-term dexamethasone pulse therapy, particularly during the initial phase of TEN, may be beneficial in reducing the mortality rate.¹⁶ However, it has been reported that neither intravenous immunoglobulins nor corticosteroids showed any significant effect on mortality in comparison with supportive care alone.²⁰

Effective treatment with intravenous fluid, corticosteroids, and oral antihistamines has also been reported.¹⁵ Treatment of skin lesions with topical application of mupirocin 0.9% NaCl and 0.5% AgNO₃ three times a day for 14 days has been described. Ocular and mucosal lesions are usually managed with supportive therapy. Successful use of laser phototherapy (LPT) for treating oral lesions has also been reported.¹⁷

In the present case, we administered 40 mg of IV methylprednisolone, associated with antimicrobial therapy, to avoid secondary infection of lesions. Dexamethasone eye drops was also used. IV corticosteroids was replaced by oral prednisone; at hospital discharge, the patient was on low maintenance dose (5 mg/day) of prednisone. This therapeutic approach, in association with efavirenz interruption and low-intensity red laser therapy, were effective in the present case, with gradual remission of the oral lesions, without secondary infection.

This case draws the attention to the presentation of oral lesions, not yet reported in the literature, which may help diagnosing other similar cases. This also indicates the need for a greater awareness on skin reaction in patients starting efavirenz, as well as the need for strict adherence to medical recommendations when efavirenz is introduced. Analgesia and acceleration of oral ulcer repair with red laser therapy are recommended in patients in these circumstances, to minimize pain and discomfort and to allow adequate patient feeding.

Conflicts of interest

The authors declare no conflicts of interest.

Funding

This work did not receive any specific grant from funding agencies in the public, commercial, or not-for-profit sectors.

REFERENCES

1. Panel on Antiretroviral Guidelines for Adults and Adolescents. Guidelines for the Use of Antiretroviral Agents in Adults and Adolescents Living with HIV. Department of Health and Human Services. Available at <http://www.aidsinfo.nih.gov/ContentFiles/AdultandAdolescentGL.pdf>. Accessed [14 December 2017].
2. Churchill D, Waters L, Ahmed N, et al. British HIV Association guidelines for the treatment of HIV-1-positive adults with antiretroviral therapy 2015. *HIV Med.* 2016;17:s2-104, <http://dx.doi.org/10.1111/hiv.12426>.
3. Brasil. Ministério da Saúde. Secretaria de Vigilância em Saúde. Departamento de DST, Aids e Hepatites Virais. Protocolo Clínico e Diretrizes Terapêuticas para Atenção Integral às Pessoas com Infecções Sexualmente Transmissíveis/Ministério da Saúde, Secretaria de Vigilância em Saúde, Departamento de DST, Aids e Hepatites Virais. – Brasília. Ministério da Saúde; 2015, 120: il. ISBN 978-85-334-2352-7.
4. Reddy RB, Shekar PC, Chandra KL, Aravind R. Oral lesions associated with Nevirapine-induced Stevens–Johnson syndrome and toxic epidermal necrolysis: a report of 10 cases. *J Oral Maxillofac Pathol.* 2013;17:431–5. PMID:24574667.
5. Kakande B, Isaacs T, Muloiwa R, Dlamini S, Lehloeny R. Case report: Stevens–Johnson syndrome following a single double dosing of nevirapine-containing regimen once in an HIV-infected woman on long-term antiretroviral therapy. *F1000 Res.* 2015;4:175. PMID: 26629333.
6. Paik S, Sen S, Era N, Saha B, Tripathi SK. Fatal Nevirapine-induced toxic epidermal necrolysis in a HIV infected patient. *J Clin Diagn Res.* 2016;10:FD03–6. PMID: 27134891.
7. Stewart A, Lehloeny R, Boulle A, de Waal R, Maartens G, Cohen K. Severe antiretroviral-associated skin reactions in South African patients: a case series and case-control

- analysis. *Pharmacoepidemiol Drug Saf.* 2016;25:1313–9. PMID:27464823.
8. Shubber Z, Calmy A, Andrieux-Meyer I, et al. Adverse events associated with nevirapine and efavirenz-based first-line antiretroviral therapy: a systematic review and meta-analysis. *AIDS.* 2013;27:1403–12. PMID: 23343913.
 9. Suárez-Lorenzo I, Castillo-Sainz R, Cárden-Santana MA, Carrillo-Díaz T. Severe reaction to emtricitabine and lamiduvine: evidence of cross-reactivity. *Contact Dermatitis.* 2016;74:253–4. PMID: 26948418.
 10. Bastuji-Garin S, Rzany B, Stern RS, Shear NH, Naldi L, Roujeau JC. Clinical classification of cases of toxic epidermal necrolysis, Stevens–Johnson syndrome, and erythema multiforme. *Arch Dermatol.* 1993;129:92–6.
 11. Al-Johani KA, Fedele S, Porter SR. Erythema multiforme and related disorders. *Oral Surg Oral Med Oral Pathol Oral Radiol Endod.* 2007;103:642–54. PMID: 17344075.
 12. Siedner-Weintraub Y, Gross I, David A, Reif S, Molho-Pessach V. Paediatric erythema multiforme: epidemiological, clinical and laboratory characteristics. *Acta Derm Venereol.* 2016. PMID: 27868144.
 13. Shah SN, Chauhan GR, Manjunatha BS, Dagrus K. Drug induced erythema multiforme: two case series with review of literature. *J Clin Diagn Res.* 2014;8:ZH01–4. PMID: 25386550.
 14. Borchers AT, Lee JL, Naguwa SM, Cheema GS, Gershwin ME. Stevens–Johnson syndrome and toxic epidermal necrolysis. *Autoimmun Rev.* 2008;7:598–605. PMID: 18603022.
 15. Paik S, Pal A, Sen S, Pramanick N, Tripathi SK. A suspected case of Efavirenz-induced Stevens–Johnson syndrome. *Drug Saf Case Rep.* 2015;2:15. PMID:10603022.
 16. Choonhakarn C, Limpawattana P, Chaowattanapanit S. Clinical profiles and treatment outcomes of systemic corticosteroids for toxic epidermal necrolysis: a retrospective study. *J Dermatol.* 2016;43:156–61. PMID: 26212378.
 17. Aggarwal H, Singh MP, Nahar P, Mathur H, Gv S. Efficacy of low-level laser therapy in treatment of recurrent aphthous ulcers - a sham controlled, split mouth follow up study. *J Clin Diagn Res.* 2014;8:218–21, <http://dx.doi.org/10.7860/JCDR/2014/7639.4064>. Epub 2014 Feb 3. PMID: 24701539.
 18. Saka B, Kombaté K, Mouhari-Toure A, et al. HIV infection and mortality in the dermatology department in Lomé, Togo. *Med Sante Trop.* 2015;25:446–8. PMID: 26742559.
 19. Tseng J, Maurer T, Mutizwa MM. HIV-Associated Toxic Epidermal Necrolysis at San Francisco General Hospital. *J Int Assoc Provid AIDS Care.* 2017;16:37–41. PMID: 26685211.
 20. Schneck J, Fagot JP, Sekula P, Sassolas B, Roujeau JC, Mockenhaupt M. Effects of treatments on the mortality of Stevens–Johnson syndrome and toxic epidermal necrolysis: a retrospective study on patients included in the prospective EuroSCAR Study. *J Am Acad Dermatol.* 2008;58:33–40. PMID: 17919775.