



The Brazilian Journal of INFECTIOUS DISEASES

www.elsevier.com/locate/bjid



Case report

Chronic skull osteomyelitis due to *Cryptococcus neoformans*: first case report in an HIV-infected patient



Natanael Sutikno Adiwardana^{a,*}, Juliana de Angelo Morás^a, Leandro Lombo Bernardo^a, Giselle Burlamaqui Klautau^b, Wladimir Queiroz^b, Jose Ernesto Vidal^{c,d,e}

^a Instituto de Infectologia Emilio Ribas, Programa de Residência Médica, São Paulo, SP, Brazil

^b Instituto de Infectologia Emilio Ribas, Departamento de Doenças Infecciosas, São Paulo, SP, Brazil

^c Instituto de Infectologia Emilio Ribas, Departamento de Neurologia, São Paulo, SP, Brazil

^d Universidade de São Paulo, Hospital das Clínicas da Faculdade de Medicina (HCFM-USP), Departamento de Doenças e Infecciosas, São Paulo, SP, Brazil

^e Universidade de São Paulo, Instituto de Medicina Tropical, Laboratório de Investigação Médica, São Paulo, SP, Brazil

ARTICLE INFO

Article history:

Received 28 September 2018

Accepted 16 November 2018

Available online 6 December 2018

Keywords:

Cryptococcus neoformans

Osteomyelitis

Skull

HIV

ABSTRACT

Osteomyelitis due to *Cryptococcus neoformans* are described in mostly 10% of patients with disseminated cryptococcosis, being direct inoculation even more uncommon. We report the case of an HIV-infected patient with history of recurring itching on his scalp and repetitive local trauma. For eighteen months, he noticed a painful and slow growing lump on his scalp. He was submitted to an excisional biopsy of the lesion but no etiological diagnosis was identified. After this procedure, the post-surgical wound never completely healed. At admission, the patient presented nausea and headache for three days and an open orifice into his skull. Investigations confirmed meningitis and skull osteomyelitis caused by *Cryptococcus neoformans*. He was treated with bone debridement and combined systemic antifungals, showing good clinical and laboratorial outcome. Cryptococcal disease should be included in the differential diagnoses of chronic osteomyelitis in HIV-infected patients and trauma is a possible source of infection.

© 2018 Sociedade Brasileira de Infectologia. Published by Elsevier España, S.L.U. This is an open access article under the CC BY-NC-ND license (<http://creativecommons.org/licenses/by-nc-nd/4.0/>).

Introduction

Globally, invasive fungal infections are responsible for a high burden of mortality and morbidity, especially in immunocompromised individuals.¹ Cryptococcosis accounts for up to 200,000 deaths per year and its mortality may reach up to

70% at three months after diagnosis, mainly in sub-Saharan Africa.²

The etiologic agent is a yeast-like, encapsulated, oval-to-spherical shaped fungus commonly found in soil and bird excreta, especially from pigeons. Classically, inhaled fungus may trigger limited to widely disseminated disease, most commonly manifesting as pulmonary and central nervous illness through hematogenous and lymphangitic spread.³ Thus, it may practically affect any organ and cause several diseases, including osteomyelitis.

* Corresponding author.

E-mail address: nateldiw@yahoo.com.br (N.S. Adiwardana).

<https://doi.org/10.1016/j.bjid.2018.11.004>

1413-8670/© 2018 Sociedade Brasileira de Infectologia. Published by Elsevier España, S.L.U. This is an open access article under the CC BY-NC-ND license (<http://creativecommons.org/licenses/by-nc-nd/4.0/>).

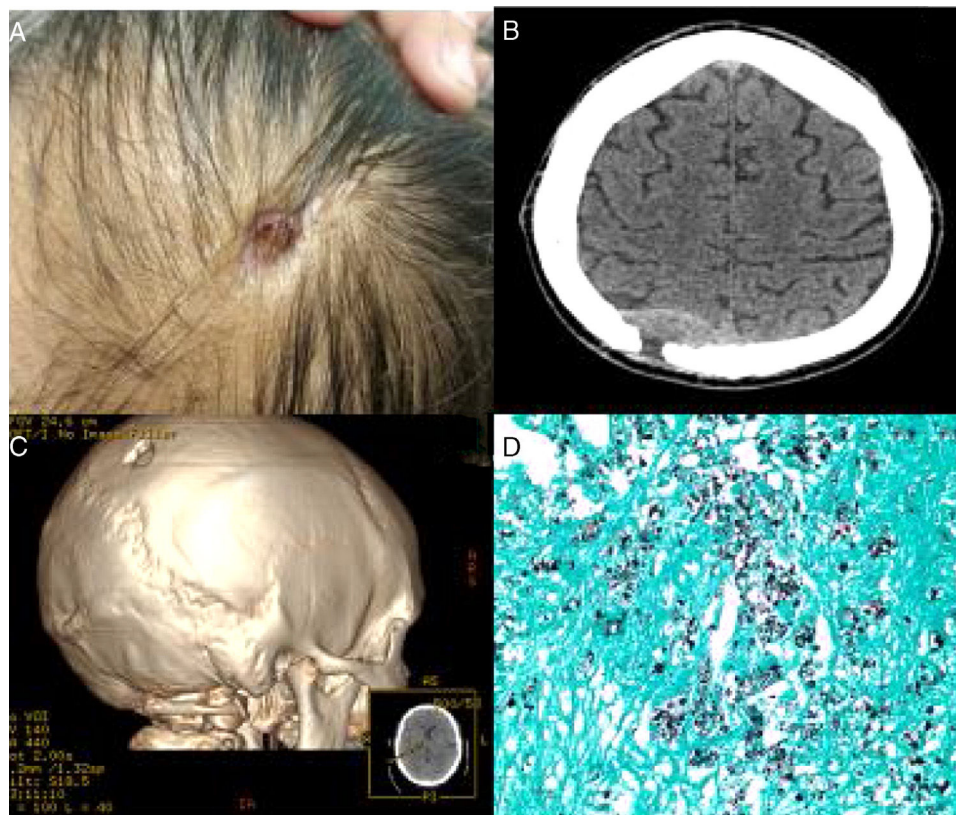


Fig. 1 – (A) External aspect of the scalp and skull lesion in an HIV-infected patient with chronic skull osteomyelitis due to *Cryptococcus neoformans*; (B) computed tomography scan of the patient's skull at admission showing parameningeal reaction with osteolytic parieto-occipital erosion; (C) three-dimensional reconstruction of the cranial lesion; (D) Grocott-Gomori methenamine-silver stain showing fungal structures compatible with *Cryptococcus*.

Cryptococcal osteomyelitis is an uncommon manifestation of disseminated disease. Skeletal cryptococcosis was described in patients with classical immunodeficiencies but also in patients with relative immunodeficiencies or without any detectable immune system suppression.³

The joints most commonly affected by cryptococcosis are the knees, elbows, hips, wrists and ankles. On the other hand, the bones most frequently affected in cryptococcosis are the vertebrae, skull, femur and ribs.³ HIV-related cryptococcal meningitis is the most frequent cause of opportunistic meningitis and skeletal involvement is rarely described.³ In this study, we report an HIV-infected patient with chronic skull osteomyelitis due to *Cryptococcus neoformans*.

Case report

Herein we report the case of a 48-year old male patient with HIV diagnosis, lymphocyte T-CD4+ cell count of 55 cells/mm³ and undetectable viral load count for over the last five years of admittance. He presented a history of chronic smoking, grade III obesity, hypertension, chronic atrial fibrillation, dyslipidemia, peripheral obstructive arterial disease and lipodystrophy. He regularly received tenofovir disoproxil fumarate, lamivudine and dolutegravir, metoprolol, losartan, aspirin, cotrimoxazole and atorvastatin. He worked as a salesman and lived in an urban area of São Paulo, Brazil and owned

three Calopsita birds, two dogs and three cats. He had a history of recurring itching on his scalp associated with a self-inflicted local trauma with a pen. Eighteen months prior to his admission, he noticed a lump on his scalp, with a gradual increase in swelling and local pain. He was submitted to an excisional biopsy of a bulging occipital-parietal lesion. The results of the biopsy were unspecific and no etiological diagnosis was identified. After this procedure, the post-surgical wound never completely healed. The patient was admitted to our service, a tertiary level hospital in São Paulo, Brazil, with headache and nausea for three days. At admission, a deep-seated ulcerated lesion of the skull was observed, affecting deep planes, down to the bone plate, in the right medial parietal area, with honey-colored crust and a small amount of serous-green discharge draining through the formed orifice (Fig. 1A). Following an examination, the first cranial computed tomography (CT) scan showed a continuity solution between skin and region of parameningeal space, with accumulation of extradural substance, besides signs of chronic osteolysis with low resorption, compatible with chronic osteomyelitis (Fig. 1B and C). The cerebrospinal fluid (CSF) analysis revealed 121 cells/mm³ (78% neutrophils), proteins of 365 mg/dL, glucose of 25 mg/dL, and negative India ink. The patient was then submitted to neurosurgical procedure with subcutaneous tissue and bone debridement. A cryptococcal antigen test using lateral flow assay in whole blood was positive, and a second CSF analysis

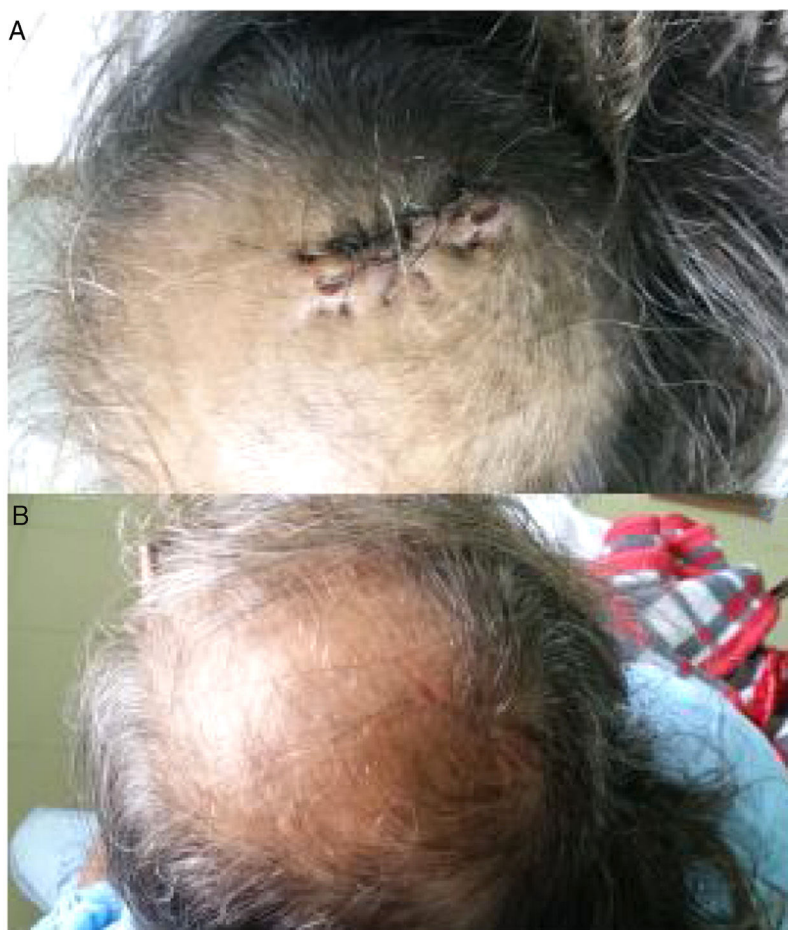

Fig. 2 – (A) One-week post-operative wound after surgical debridement of chronic skull osteomyelitis in an HIV-infected patient. (B) Three-week post-operative wound aspect.

showed 75 cells/mm³ (90% neutrophils), proteins of 250 mg/dL, glucose of 36 mg/dL, negative India ink and positive cryptococcal antigen test using lateral flow assay. In bone tissue, direct fungal exam was compatible with yeast of *Cryptococcus* and culture showed *C. neoformans* (Fig. 1D). In addition, CSF culture confirmed the presence of this fungus. Chest X-ray and CT were normal. The patient received amphotericin B deoxycholate 50 mg/day and 5-fluocytosine 100 mg/kg/day. After five days, there was significant improvement of all symptoms. Nevertheless, after 15 days of treatment, the patient presented acute renal injury and anemia. Thus, his antifungal treatment was changed to amphotericin lipid complex and fluconazole 800 mg/day. Finally, after 29 days of treatment, the patient was asymptomatic and showed negative fungal cultures of his CSF, being discharged and using fluconazole 400 mg/day up to complete 10 weeks of treatment and switching to on fluconazole 200 mg/day. The surgical wound showed signs of adequate cicatrization throughout hospitalization and later on during follow up, without complications (Fig. 2A and B). One year later, the patient remained asymptomatic with a T-CD4+ lymphocyte cell count of 41 cells/mm³ and undetectable viral load.

Discussion

To the best of our knowledge, the present report represents the first case of an HIV-infected patient with chronic skull osteomyelitis due to *C. neoformans*.

Skeletal infections as manifestations of cryptococcal disease are described in only 5% to 10% of patients with disseminated disease. In the skull, its manifestations are even scarcer. Until 2011, there were only 14 similar cases published.³ The most classical clinical manifestation of skull osteomyelitis by *Cryptococcus* consists of a progressive soft exophytic or swollen masses, with or without pain, sometimes with fever and evolving from acute onset to three years of development,³ consistent with the history of our patient.

Direct inoculation is an uncommon form of origin of cryptococcal bone disease, with only four cases described previously in the literature.¹ In our case, a history of direct repetitive trauma and the chronology of clinical manifestations may suggest that skull disease preceded meningeal and bloodstream involvement. Notwithstanding, the possibility

that a reactivation of a latent reservoir in a long-standing immunosuppressed HIV patient should also be considered.

Interestingly, our patient maintains severe immunosuppression despite regular antiretroviral treatment and sustained undetectable viral load. This fact may have allowed the progression of the disease after the repetitive skull trauma or the reactivation of a latent reservoir, as cited before.

In HIV patients, meningitis is the main manifestation of cryptococcosis and causes high mortality, particularly in developing countries. Skeletal cryptococcosis in HIV-infected patients has been described only in four patients: two cases involving the knee, one on the lumbar vertebrae and the last on the sternum, elbow and ribs.^{3,4}

Skeletal cryptococcosis is a diagnostic challenge. Erythrocyte sedimentation rate is usually high. Diagnosis is usually confirmed by open biopsies (~70%) followed by other invasive methods such as aspiration (~25%), incision and drainage (~6%). Nowadays, it is recommended to prioritize aspiration over open biopsies when possible to minimize invasiveness. Bone, serum and CSF cultures to diagnose cryptococcal osteomyelitis appear to be highly sensitive rate (~100%).³ Latex antigen and lateral flow assay are recommended for disseminated and meningeal involvement. Lateral flow assay performed in whole blood is an important point-of-care tool and was the first positive test in our patient. Radiological imaging in skeletal cryptococcosis is usually altered (~85% of cases).³ Tomographic findings may show well-defined, irregular lytic lesions ranging from two to five cm in diameter, sometimes showing bone sequestrum, also suggesting dura mater involvement in half of them.⁴ Periosteal reaction can appear in some cases (~15%), and osteomyelitis is a rather common finding in most scanned patients (~65%).³ As with other cases of osteomyelitis, follow up requires serial radiological imaging.³

There is no standardized treatment for cryptococcal osteomyelitis. Based on the experience with other forms

of cryptococcosis and using the principles of bacterial osteomyelitis management, both surgical debridement and prolonged combined antifungal therapy seems to be reasonable. In this regard, our patient had undergone surgery and four weeks of induction therapy.

In conclusion, cryptococcal disease should be included in the differential diagnoses of chronic osteomyelitis in HIV-infected patients and repetitive trauma is a possible source of direct inoculation of *C. neoformans*.

Funding

This research did not receive any specific grant from funding agencies in the public, commercial, or not-for-profit sectors.

Conflicts of interest

The authors declare no conflicts of interest.

REFERENCES

1. Pudipeddi A, Liu K, Watson G, Davis R, Strasser S. Cryptococcal osteomyelitis of the skull in a liver transplant patient. *Transpl Infect Dis.* 2016, <http://dx.doi.org/10.1111/tid.12602>. Accepted June 26, 2016.
2. Limper AH, Adenis A, Le T, Harrison TS. Fungal infections in HIV/AIDS. *Lancet Infect Dis.* 2017, [http://dx.doi.org/10.1016/S1473-3099\(17\)30303-1](http://dx.doi.org/10.1016/S1473-3099(17)30303-1). Published online July 31, 2017.
3. Zhou HX, Lu L, Chu T, et al. Skeletal cryptococcosis from 1977 to 2013. *Front Microbiol.* 2015, <http://dx.doi.org/10.3389/fmicb.2014.00740>. Published online January 14, 2015.
4. Corral JE, Lima S, Quezada J, Samayoa B, Arathoon E. Cryptococcal osteomyelitis of the skull. *Med Mycol.* 2011;49:667-71. Published online February 8, 2011.