



The Brazilian Journal of INFECTIOUS DISEASES

www.elsevier.com/locate/bjid



Clinical image

Tungiasis in a Colombian patient



Claudia J. Díaz^{a,*}, Kevin Escandón-Vargas^{b,*}

^a School of Dermatology and Dermatological Surgery, Hospital Universitario del Valle, Universidad del Valle, Cali, Colombia

^b School of Medicine, Universidad del Valle, Cali, Colombia

ARTICLE INFO

Article history:

Received 28 November 2016

Accepted 16 December 2016

Available online 10 March 2017

A 60-year-old male pig-farm worker from a rural area of Colombia was referred to our clinic with history of itchy skin lesions on the soles in the last two months. The patient reported often walking barefoot. Physical exam revealed clusters of monomorphic yellowish-brown papules and nodules with central black dots and indurated halos on the soles (Figs. 1 and 2). Treatment consisted of surgical extraction of embedded fleas from the lesions (Fig. 3) and adjuvant keratolytics. A flea (*Tunga* spp.) and its eggs were visualized with light microscopy in one of the excised lesions (Fig. 4). At clinical follow-up, the patient had recovered completely.

Tungiasis is an ectoparasitic skin disease caused by the penetration of the pregnant female sand flea *Tunga* spp. into the epidermis.^{1,2} This neglected tropical disease is an important healthcare issue due to its significant morbidity and endemicity in several Latin American countries, the Caribbean, and sub-Saharan Africa, particularly in resource-poor communities.³ However, several cases have been reported throughout the world in travelers returning from endemic areas. Although any location of the skin can be affected, lesions predominantly occur on the feet after contact with sand or sandy soil containing fleas. In some instances, tungiasis is associated with physical disability, chronic pain, skin complications and secondary bacterial superinfections.^{1,2} Diagnosis is clinical and may be

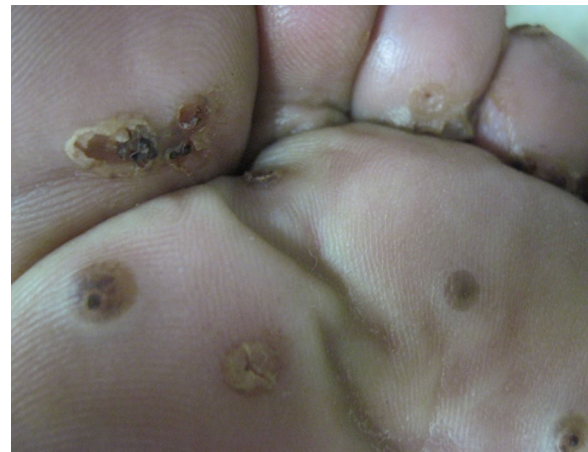

Fig. 1 – Multiple yellowish-brown papules and nodules affecting the interdigital spaces and the sole of the left foot.

challenging even to physicians in endemic areas as the clinical presentation varies with the developmental stages of the flea. An effective treatment involves excision of the fleas. Both people living in endemic places and travelers visiting these places should be advised to permanently wear closed

* Corresponding authors.

E-mail addresses: clajudiaz@yahoo.com (C.J. Díaz), kevin.escandonvargas@gmail.com (K. Escandón-Vargas).

<http://dx.doi.org/10.1016/j.bjid.2016.12.010>

1413-8670/© 2017 Sociedade Brasileira de Infectologia. Published by Elsevier Editora Ltda. This is an open access article under the CC BY-NC-ND license (<http://creativecommons.org/licenses/by-nc-nd/4.0/>).

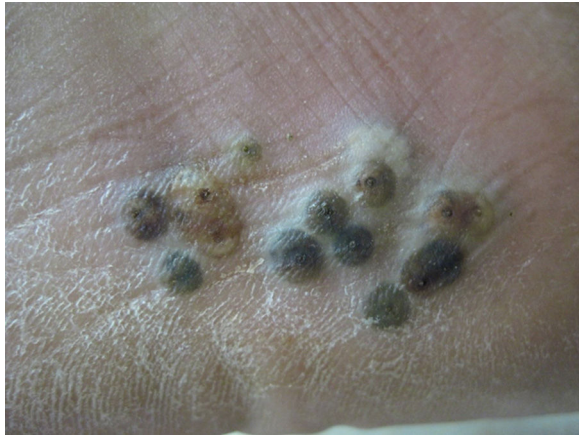

Fig. 2 – Multiple yellowish-brown papules and nodules with central black spots (the posterior end of the fleas) and indurated halos on the patient's left sole. Xerosis is also observed.

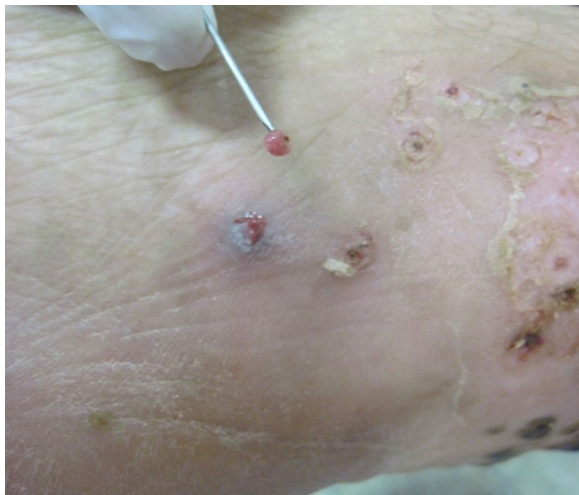

Fig. 3 – Surgical extraction of a flea with a sterile needle.

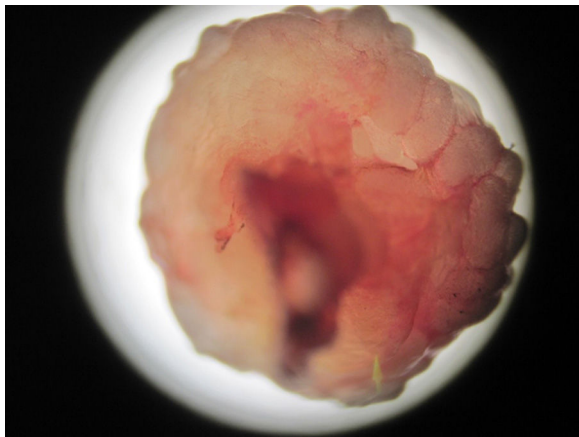


Fig. 4 – *Tunga* spp. and its eggs visualized from one of the excised lesions.

shoes and socks. It has been shown that prevention of re-infestation leads to a reduction of the morbidity associated with tungiasis.⁴

Author contributions

Claudia J. Díaz contributed to conception of the manuscript and data acquisition.

Kevin Escandón-Vargas drafted the manuscript and made the literature review.

Both authors gave final approval of the version to be published.

Conflicts of interest

The authors declare no conflicts of interest.

REFERENCES

1. Pampiglione S, Fioravanti ML, Gustinelli A, et al. Sand flea (*Tunga* spp.) infections in humans and domestic animals: state of the art. *Med Vet Entomol.* 2009;23:172–86.
2. Lefebvre M, Capito C, Durant C, Hervier B, Grossi O. Tungiasis: a poorly documented tropical dermatosis. *Med Mal Infect.* 2011;41:465–8.
3. Miller H, Rodríguez G. Tungiasis in native Amerindians in Vaupés province: epidemiology, clinical aspects, treatment, and prevention. *Biomedica.* 2010;30:215–37.
4. Thielecke M, Raharimanga V, Stauss-Grabo M, Rogier C, Richard V, Feldmeier H. Regression of severe tungiasis-associated morbidity after prevention of re-infestation: a case series from rural Madagascar. *Am J Trop Med Hyg.* 2013;89:932–6.