



# The Brazilian Journal of INFECTIOUS DISEASES

[www.elsevier.com/locate/bjid](http://www.elsevier.com/locate/bjid)



## Clinical image

# An unusual imported case of diphyllobothriosis in Mexico

Elba G. Rodríguez-Pérez<sup>a,\*</sup>, Kevin Escandón-Vargas<sup>b</sup>, Jenniffer A. Castellanos<sup>c</sup>

<sup>a</sup> Parasitología Clínica, Hospital Universitario, Universidad Autónoma de Nuevo León, Monterrey, México

<sup>b</sup> Escuela de Medicina, Facultad de Salud, Universidad del Valle, Cali, Colombia

<sup>c</sup> Departamento de Morfología, Facultad de Salud, Universidad del Valle, Cali, Colombia

## ARTICLE INFO

### Article history:

Received 4 October 2016

Accepted 8 October 2016

Available online 23 December 2016

A 7-year-old Mexican male presented to a hospital in Monterrey, Mexico with a 1-week history of persistent abdominal discomfort and loose stools. One month before presentation, the patient had traveled on vacation to Cuba and recalled eating ceviche (a popular raw fish dish in Latin America). He denied vomiting, anorexia, fever or weight loss, and had no other significant medical history. Physical exam was unremarkable. Routine blood and biochemical tests were normal.

An upper endoscopy detected a larva attached to the duodenal wall. After endoscopic extraction of the worm, symptoms were relieved. Further examination of the larva allowed identification of a plerocercoid larva of *Diphyllobothrium* sp. (Fig. 1) based on the morphological and histological features described in previous publications.<sup>1,2</sup> The larva measured 2.8 cm in length. The epithelial morphology of the dorso-ventrally flattened larva's body was typical, with apparent segmentation, traces of the bothria in the anterior end, and invagination at the posterior end. The mid-body presented a single poorly developed layer of subtegumentary longitudinal musculature. Diagnosis of the worm at the species level was not achieved because the adult stage was needed and molecular confirmation was not possible.

Here, we report the first diphyllobothriosis case in Mexico, which was imported from Cuba. Diphyllobothriosis is a widespread fish-borne zoonosis acquired by eating raw or undercooked fish contaminated with plerocercoid larvae of the tapeworm *Diphyllobothrium*.<sup>3,4</sup> Common raw or poorly cooked fish dishes include sushi, sashimi, ceviche, carpaccio, and others. The disease is endemic in the Arctic regions and several parts of Europe, Asia, and the Americas. Given that the disease is usually caused by the adult form of *Diphyllobothrium* spp., we consider this to be an unusual case presentation in which the larva, attached with its scolex to the intestinal epithelium, was found before becoming an adult.

## Author contributions

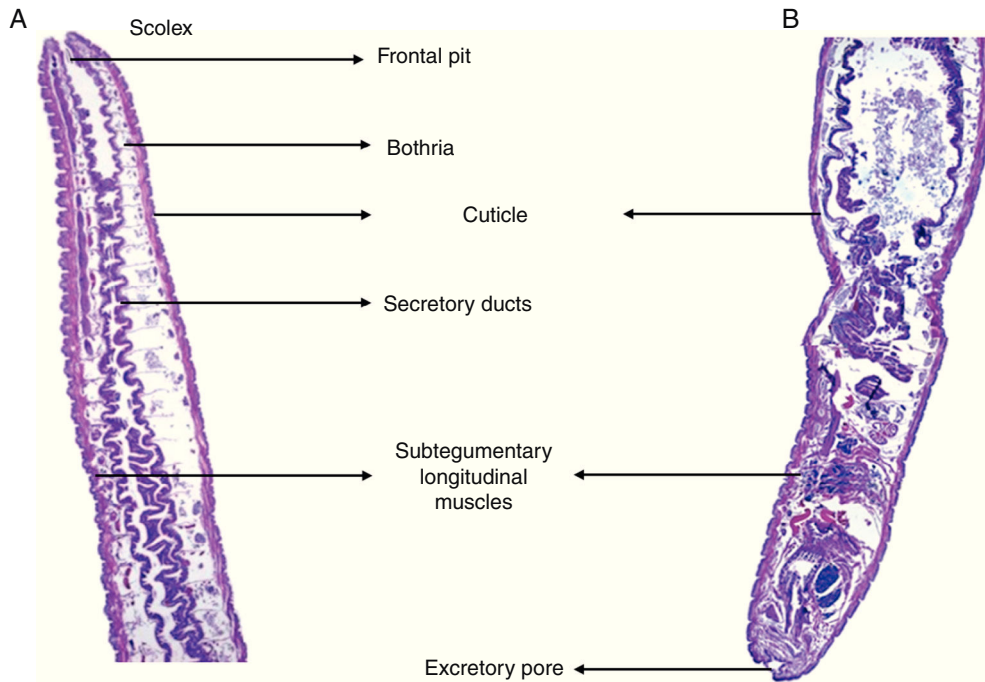
Elba G. Rodríguez-Pérez took part in conception of the manuscript and data acquisition. Kevin Escandón-Vargas drafted the manuscript and reviewed the literature. Jenniffer A. Castellanos contributed to the analysis and interpretation of data.

\* Corresponding author.

E-mail address: [egrope@yahoo.com](mailto:egrope@yahoo.com) (E.G. Rodríguez-Pérez).

<http://dx.doi.org/10.1016/j.bjid.2016.10.015>

1413-8670/© 2016 Published by Elsevier Editora Ltda. on behalf of Sociedade Brasileira de Infectologia. This is an open access article under the CC BY-NC-ND license (<http://creativecommons.org/licenses/by-nc-nd/4.0/>).



**Fig. 1 – Longitudinal histological section of the *Diphyllobothrium* sp. plerocercoid larva recovered from the patient (hematoxylin–eosin stain). (A) Anterior end. (B) Mid-body and posterior end.**

### Conflicts of interest

The authors declare no conflicts of interest.

### REFERENCES

1. Andersen K. A marine *Diphyllobothrium* plerocercoid (Cestoda, Pseudophyllidea) from blue whiting (*Micromestius poutasson*). *Z Parasitenkd.* 1977;52:289–96.
2. Andersen KI, Gibson DI. A key to three species of larval *Diphyllobothrium* Cobbold, 1858 (Cestoda: Pseudophyllidea) occurring in European and North American freshwater fishes. *Syst Parasitol.* 1989;13:3–9.
3. Scholz T, Garcia HH, Kuchta R, Wicht B. Update on the human broad tapeworm (genus *Diphyllobothrium*), including clinical relevance. *Clin Microbiol Rev.* 2009;22:146–60.
4. Kuchta R, Scholz T, Brabec J, Narduzzi-Wicht B. Chapter 17. *Diphyllobothrium*, *Diplogonoporus* and *Spirometra*. In: Xiao L, Ryan U, Feng F, editors. *Biology of foodborne parasites. Section III important foodborne helminths.* Boca Raton, Florida: CRC Press; 2015. p. 299–326.