



The Brazilian Journal of INFECTIOUS DISEASES

www.elsevier.com/locate/bjid



Clinical image

Total abdominal aortic occlusion: a complication of brucellosis



Cafer Korkut^a, Gonul Sengoz^{b,*}, Esra Bilgi^c

^a Bagcilar Training and Research Hospital, Infectious Diseases and Clinical Microbiology, Istanbul, Turkey

^b Haseki Training and Research Hospital, Infectious Diseases and Clinical Microbiology, Istanbul, Turkey

^c Bagcilar Training and Research Hospital, Radiology, Istanbul, Turkey

ARTICLE INFO

Article history:

Received 23 November 2014

Accepted 30 November 2014

Available online 27 January 2015

Common and applicable diagnostic methods are available for brucellosis. However, its life-threatening complications remain critical. Herein we present a 68-year-old patient who complained of leg pain for two months. At admission he had absent pulse in the left femoral and bilateral popliteal arteries. Laboratory test results were leucocytes $8700/\text{mm}^3$, CRP 86 mg/L , and ESR 47 mm/h . Abdominal CT revealed images consistent with mural thrombus in the suprarenal segment of abdominal aorta, total occlusion and hypodense thrombus material completely filling the aortic lumen through infrarenal segment extending to lumens of the caudal, bilateral common and superior iliac arteries (Figs. 1-3). No paleness, coldness or color change was detected in the lower extremities. The patient had fever, right inguinal swelling, and sweating. Abdominal CT showed an aortic thrombus and a hypodense lesion of $58 \text{ mm} \times 61 \text{ mm} \times 100 \text{ mm}$ in the right psoas muscle. The repeated Brucella STA test was positive in 1:5120 titer. USG-guided drainage of the psoas abscess was performed and a treatment with doxycycline and rifampicin was administered for three months (Fig. 4). The patient was not operated on and progressed with no clinical complaints.

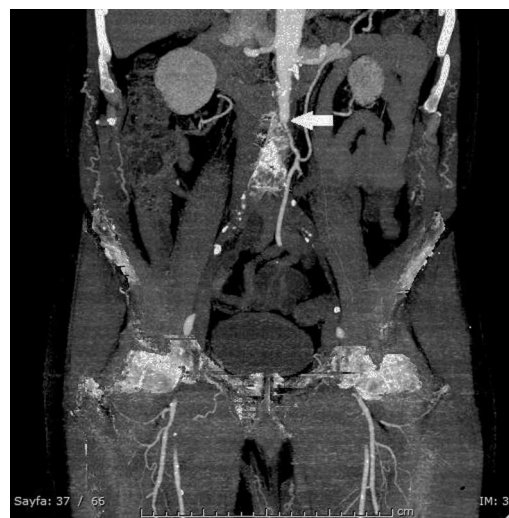

Fig. 1 – In the coronal section of the intravenous contrast-enhanced abdominal CT; initial localization of the infrarenal occlusion in the abdominal aorta (arrow).

* Corresponding author at: Haseki Eğitim ve Araştırma Hastanesi, Enfeksiyon Hastalıkları ve Klinik Mikrobiyoloji Kliniği, Adnan Adıvar Cad., Fatih/İstanbul, Turkey.

E-mail address: gonulsengoz@gmail.com (G. Sengoz).

<http://dx.doi.org/10.1016/j.bjid.2014.11.005>

1413-8670/© 2015 Elsevier Editora Ltda. All rights reserved.

Brucellosis cases with aortic occlusions and thrombus have been very rarely reported in the literature. This complication is mostly fatal in acute cases. This complication should be kept in mind especially for the patients complaining of lower

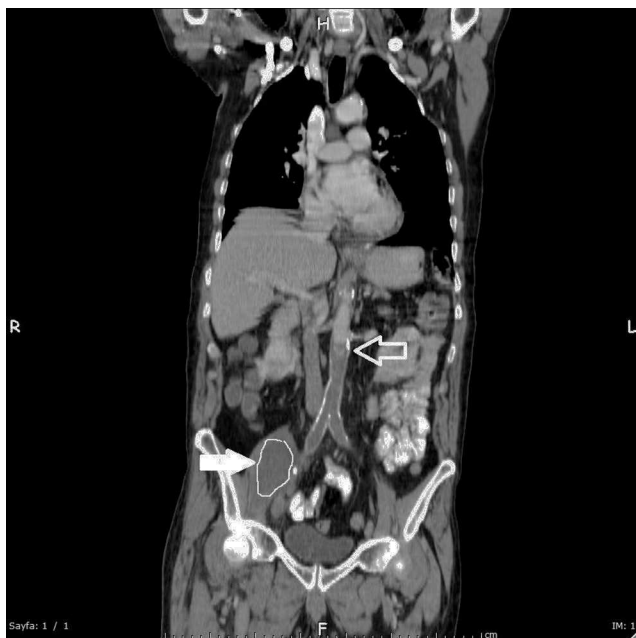

Fig. 2 – In the coronal section of the oral and intravenous contrast-enhanced abdominal CT; initial localization of the infrarenal occlusion in the abdominal aorta (hollowarrow), a hypodense heterogeneous abscess leading to expansion of right psoas muscle (arrow).

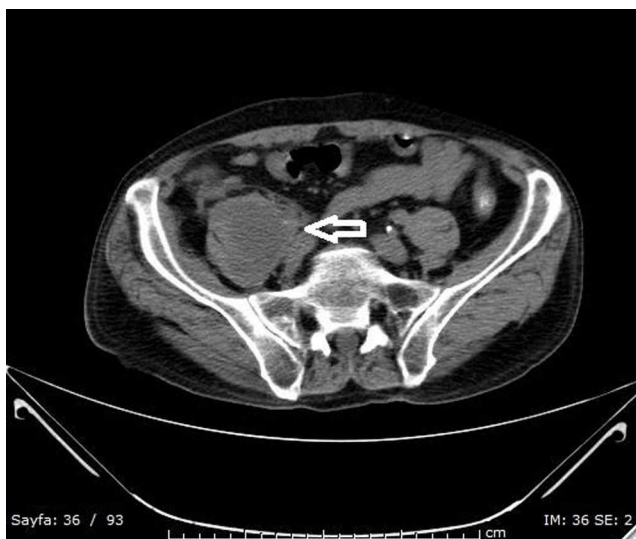

Fig. 3 – In the axial non-contrast abdominal CT; formation of a hypodense heterogeneous abscess leading to expansion of right psoas muscle which is accompanied by increased densities in the neighboring fatty tissue (hollowarrow).

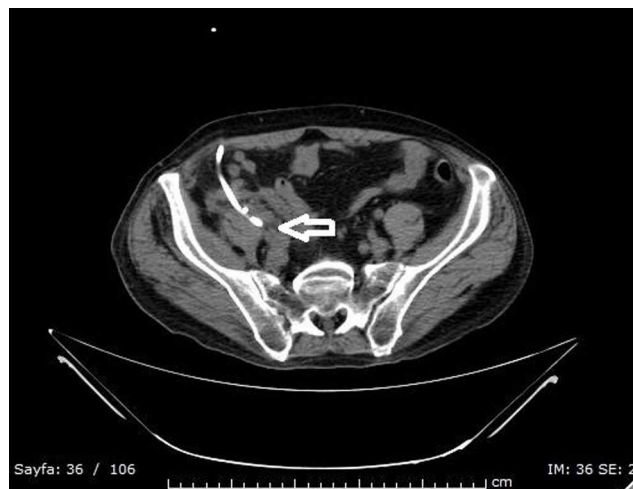


Fig. 4 – In the non-contrast axial section of the abdominal CT; drainage catheter extending to abscess area in the right psoas muscle (hollowarrow).

extremity pain. Such pain may result from impaired circulation due to aortic thrombus, as well as from sacroiliitis and spondylodiscitis. The treatment approach for these patients in whom chronic thrombus developed without any symptom is not yet clear.¹⁻³

Conflicts of interest

The authors declare no conflicts of interest.

REFERENCES

1. Sanchez-Gonzales J, Garcia-Delange T, Martos F, Colmenero JD. Thrombosis of the abdominal aorta secondary to *Brucella* spondylitis. *Infection*. 1996;24:261-2.
2. Colomba C, Siracusa L, Rubino R, et al. A case of *Brucella* endocarditis in association with subclavian artery thrombosis. *Case Rep Infect Dis*. 2012, <http://dx.doi.org/10.1155/2012/581489>. Article ID 581489, 3 pp.
3. Cascio A, De Caridi G, Lentini S, et al. Involvement of the aorta in brucellosis: the forgotten, life-threatening complication: a systematic review. *Vector Borne Zoonotic Dis*. 2012;12: 827-40.