



The Brazilian Journal of INFECTIOUS DISEASES

www.elsevier.com/locate/bjid



Clinical image

Bilateral geographical ulcer in a neonate

Priyanka Arora^a, Suma Ganesh^a, Kamaldeep Arora^b, Rashmi Ranjan Das^{c,*}

^a Department of Pediatric Ophthalmology & Strabismus, Dr Shroff's Charity Eye Hospital, New Delhi, India

^b Department of Pediatrics, Dayanand Medical College and Hospital, Ludhiana, India

^c Department of Pediatrics, All India Institute of Medical Sciences, Bhubaneswar, India

ARTICLE INFO

Article history:

Received 6 July 2013

Accepted 7 July 2013

Available online 24 October 2013

A 14-day-old neonate presented with excessive crying and not opening the eyes since last one week. She was afebrile and had a normal overall general condition. There was a vesicular rash near the left nasolabial fold. On examination under anesthesia, large geographical ulcer involving three-fourths of the cornea with stromal edema was present in both the eyes (Fig. 1). The pupil and iris pattern were normal. Keeping the possibility of primary herpes simplex keratitis, direct immunofluorescent staining of vesicle fluid was done. The test was positive for herpes simplex virus (HSV) 2. Cerebrospinal fluid (CSF) examination was normal including the PCR for HSV. On probing the history, the antenatal period was uneventful, and the mother did not have any history of fever, rash, vaginal discharge or genital lesion. However, maternal IgG was positive for HSV 1 and 2 antibodies. Both topical and systemic acyclovir were prescribed. After three weeks, the skin and corneal lesions had healed.

Many neonatal infections occur because of asymptomatic cervical shedding of virus, usually after a primary episode of HSV infection.¹ Diagnosis requires a high index of suspicion because the history of an active infection, primary or secondary, in a mother is often not given, as in the index case. Any vesicular rash in an infant up to eight weeks of age should be cultured and the infant immediately started on antiviral therapy with acyclovir pending culture results. Ocular involvement occurs in 20% of cases of neonatal herpes.^{1,2} The infant is protected for the first few months of life by circulating maternal antibodies, but this might not be the case always.¹ Ocular involvement ranges from mild keratoconjunctivitis to severe retinitis.² Rarely, bilateral ocular involvement can be seen. The diagnosis is entirely clinical, and prompt therapy is essential because of risk of dissemination.³

* Corresponding author at: Department of Pediatrics, AIIMS, Bhubaneswar 751019, India.

E-mail address: dr_rashmipgi@yahoo.com (R.R. Das).

1413-8670 © 2013 Elsevier Editora Ltda. Este é um artigo Open Access sob a licença de CC BY-NC-ND

<http://dx.doi.org/10.1016/j.bjid.2013.07.005>

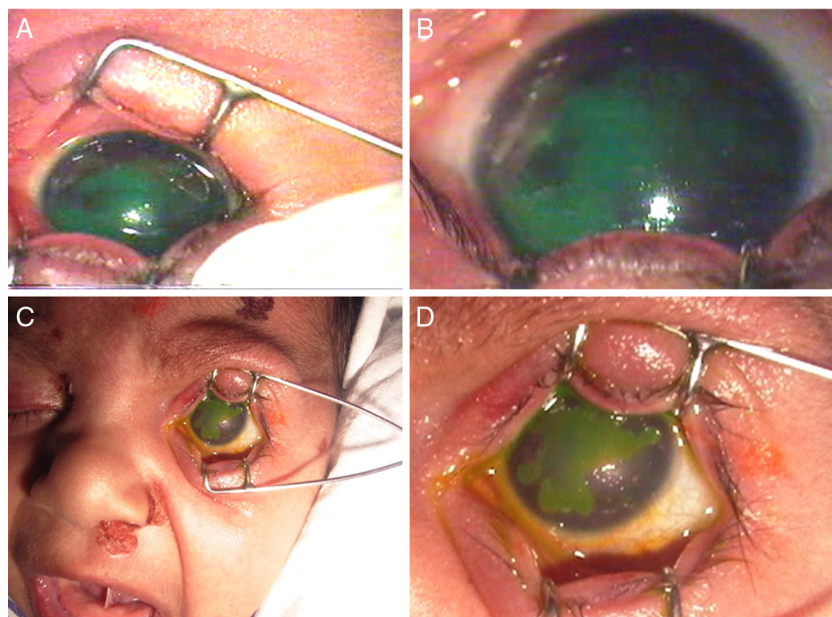


Fig. 1 – (A and B) Right eye showing a large geographic ulcer (stained). (C and D) Left eye showing a large geographic ulcer (stained). (C) Vesicular rash near left nasolabial fold.

Conflicts of interest

The authors declare no conflicts of interest.

REFERENCES

1. Kimberlin DW. Neonatal herpes simplex infection. *Clin Microbiol Rev.* 2004;17:1-13.

2. Liesegang TJ. Herpes simplex virus epidemiology and ocular importance. *Cornea.* 2001;20:1-13.
3. Pinninti SG, Kimberlin DW. Maternal and neonatal herpes simplex virus infections. *Am J Perinatol.* 2013;30:113-20.