



The Brazilian Journal of INFECTIOUS DISEASES

www.elsevier.com/locate/bjid



Case report

Dilated cardiomyopathy and hypothyroidism associated with pegylated interferon and ribavirin treatment for chronic hepatitis C: case report and literature review

Wenxue Zhao^a, Fanpu Ji^{a,*}, Shanshan Yu^b, Zongfang Li^c, Hong Deng^a

^a Department of Infectious Disease, The Second Affiliated Hospital, College of Medicine, Xi'an Jiaotong University, Xi'an, China

^b Department of Ultrasound Medicine, The Second Affiliated Hospital, College of Medicine, Xi'an Jiaotong University, Xi'an, China

^c Department of Hepatology and Surgery, The Second Affiliated Hospital, College of Medicine, Xi'an Jiaotong University, Xi'an, China

ARTICLE INFO

Article history:

Received 20 February 2013

Accepted 23 May 2013

Available online 10 October 2013

Keywords:

Pegylated interferon

Adverse drug reaction

Cardiotoxicity

Thyroid dysfunction

ABSTRACT

Pegylated interferon alpha (Peg IFN- α) in combination with ribavirin is the backbone of treatment in chronic hepatitis C (CHC). Cardiotoxicity due to interferon therapy is rare. The most frequent cardiovascular complications are arrhythmias and ischemic manifestations. Cardiomyopathy is extremely rare but can be life threatening. We present the case of a 41-year-old female patient with CHC in whom Peg IFN- α induced dilated cardiomyopathy and hypothyroidism. Chest radiography showed an enlarged and globular cardiac silhouette and pulmonary congestion. Echocardiography showed decreased left ventricular systolic function with an ejection fraction of 32% and fractional shortening of 15%. Cardiomyopathy had a complete remission after cessation of antiviral therapy with short-term heart failure medications and supportive care. Then we review the current literature about interferon induced cardiomyopathy in patients with HCV infection, as well as share our clinical experience in diagnosing and managing this rare complication.

© 2013 Elsevier Editora Ltda. Este é um artigo Open Access sob a licença de [CC BY-NC-ND](http://creativecommons.org/licenses/by-nc-nd/3.0/)

Introduction

Hepatitis C virus (HCV) is a major public health problem, involving approximately 170 million people worldwide.¹ Pegylated interferon- α (Peg IFN- α) in combination with ribavirin is the backbone of treatment in patients with HCV infection before direct-acting antiviral agents (DAAs) became available, and still is the optimal choice for the majority of patients with CHC. Interferon- α (IFN- α)-induced thyroid dysfunction (TD) has been well documented, with an incidence ranging from

10% to 27.7%.²⁻⁶ Cardiovascular complications caused by interferon consists mainly of arrhythmia, myocarditis, reversible hypertension, ischemic heart disease, pericarditis and pericardial effusion.⁷⁻¹⁰ However, few cases of interferon-induced cardiomyopathy have been reported.^{7,8,11-13} We herein report a patient with CHC in whom previous standard IFN- α plus ribavirin had not induced severe complications, while Peg IFN- α did induce dilated cardiomyopathy and hypothyroidism. Cardiomyopathy had a complete remission after cessation of Peg IFN- α and ribavirin. However, permanent thyroid hormone replacement therapy is needed to treat hypothyroidism.

* Corresponding author at: Department of Infectious Disease, The Second Affiliated hospital, College of Medicine, Xi'an Jiaotong University, 157 Xi Wu Road, Xi'an, Shaanxi 710004, People's Republic of China.

E-mail address: jifanpu1979@163.com (F. Ji).

1413-8670 © 2013 Elsevier Editora Ltda. Este é um artigo Open Access sob a licença de [CC BY-NC-ND](http://creativecommons.org/licenses/by-nc-nd/3.0/)

<http://dx.doi.org/10.1016/j.bjid.2013.05.014>

Case presentation

A 41-year-old woman without history of heart disease was admitted to our hospital with 2-week history of gradually increasing dyspnea and fatigue in June 2008. She had a history of rheumatoid arthritis for 10 years and was not receiving any medications. Chronic hepatitis C had been diagnosed in 2006, and HCV genotype was 2a. After initial therapy with IFN- α -2b (3 MU, 3 times weekly) and ribavirin (800 mg/d) for six months, HCV RNA was undetectable by polymerase chain reaction at the end of treatment and six months follow-up. In January 2008, the patient consulted for CHC when she began to experience generalized malaise and fatigue. The patient's baseline chest radiograph showed normal lung fields and no cardiomegaly, and an electrocardiogram was normal. Laboratory tests revealed an alanine aminotransferase (ALT) level of 174 U/L (normal up to 40 U/L), aspartate aminotransferase (AST) level of 123 U/L (normal up to 40 U/L), and positive serology for HCV. The HCV RNA level was 546,000 IU/mL. The patient refused liver biopsy prior to the second course of interferon therapy. Combination therapy was initiated with Peg IFN- α -2a at the dose of 180 μ g per week in combination with ribavirin at the dose of 800 mg daily. The patient responded well, her aminotransferase levels normalized, and HCV RNA was undetectable at week 4. After the twelfth week of treatment, the patient was treated with levothyroxine for hypothyroidism without discontinuation of antiviral therapy.

Physical examination revealed blood pressure of 130/90 mmHg, heart rate of 122/min, a dilated jugular vein, and an audible gallop rhythm and systolic ejection murmur. There was mild peripheral edema. Chest radiography showed an enlarged and globular cardiac silhouette and pulmonary congestion without pleural effusion (Fig. 1). Serum free T3, T4, total T3, T4 and thyroid stimulating hormone (TSH) were within normal values with levothyroxine replacement therapy at a dose of 50 μ g daily. Cardiac enzymes, liver enzymes, erythrocyte sedimentation rate and C reactive protein were normal. Antinuclear, antithyroid peroxidase and antithyroglobulin antibodies were positive. Rheumatoid

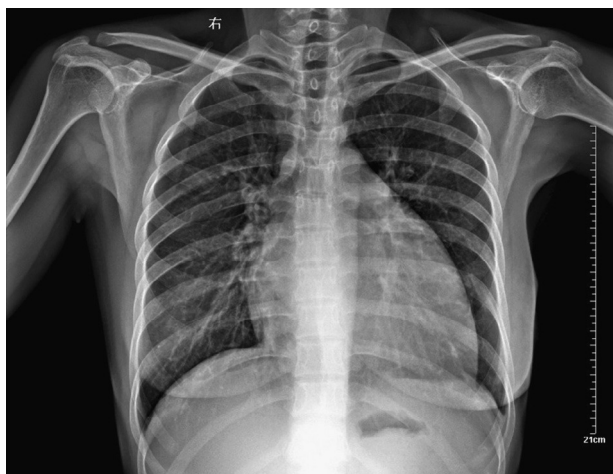

Fig. 1 – Chest radiography showed an enlarged and globular cardiac silhouette and pulmonary congestion without pleural effusion.

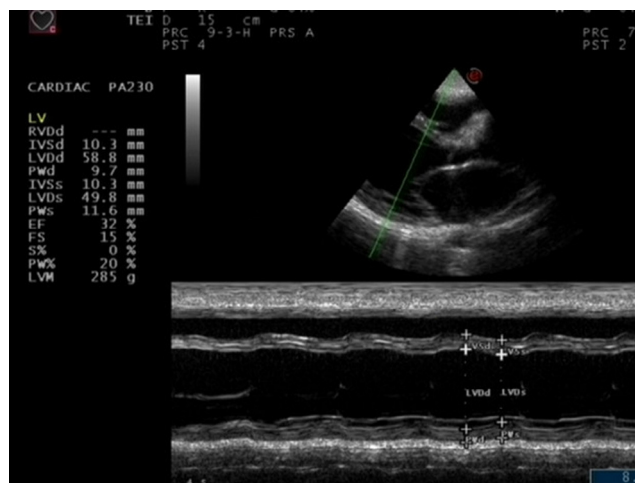


Fig. 2 – Echocardiography showed decreased left ventricular systolic function, including descending ejection fraction and fractional shortening.

factor and anti- α -myosin antibodies were absent. *Coxsackie virus*, *Chlamydia pneumoniae* and *Mycoplasma pneumoniae* serology were negative. Echocardiography showed decreased left ventricular systolic function with an ejection fraction (EF) of 32% and fractional shortening (FS) of 15%, as well as dilated left ventricle with decreased wall motion of entire left ventricle (Fig. 2). Dilated cardiomyopathy and hypothyroidism secondary to Peg IFN α -2a was suspected. Therefore, Peg IFN- α and ribavirin was discontinued after 23 weeks of treatment. The patient was treated with Benazepril, Digoxin, Furosemide, Metoprolol Succinate and Levothyroxine. Her symptoms improved in one week and she was discharged on the same medications. A second echocardiogram three months later showed an EF of 47% with normal chambers, and heart failure medications were discontinued. She maintained normal aminotransferases and undetectable HCV RNA after 24 months of follow up. However, she needs permanent thyroid hormone replacement therapy for hypothyroidism.

Discussion

Peg IFN- α in combination with ribavirin was the historical backbone of treatment in patients with HCV infection in the past decade, and will still be the optimal choice for the majority of patients with CHC. As a result, the safety of combination therapy is going to remain a major issue for patients with CHC. Although cardiovascular complications from IFN- α are scarce, the growing number of patients receiving Peg IFN- α therapy will undoubtedly lead to an increasing number of patients with cardiotoxicity. Out of these complications, arrhythmia and ischemic heart disease are the predominant types, followed by myocarditis and reversible hypertension, while cardiomyopathy is rare.^{7,8} To the best of our knowledge, only six cases of cardiomyopathy associated with IFN- α treatment for chronic hepatitis C has been described to date in English literature, including our case.^{7,12,13} The clinical data of the six cases are shown in Table 1.

Table 1 – Case reports of cardiomyopathy associated with interferon- α therapy for HCV in the literature.

Authors/years	Age/sex	Administered	Duration of IFN therapy	Medical history	Other toxicity	Treatment	Outcome
Teragawa et al. ⁸	59/F	Natural IFN- α^a	19 wk	Hypertension	N/A	D + S	Resolved
	57/F	Recombinant IFN- α -2b ^a	6 wk	None	N/A	D + S	Resolved
Condat et al. ¹²	45/M	Peg IFN- α -2b	24 wk	Palpitations	Pleural effusion	D + S	Death
Choy-Shan et al. ¹³	49/M	Peg IFN- α	36 wk	Hypertension/DM	None	D + S + BK	No resolved
	64/M	Peg IFN- α	48 wk	DM	None	D + S	N/A
Current case	41/F	Peg IFN- α -2a	23 wk	RA	Hypothyroidism	D + S	Resolved

Peg IFN- α , pegylated interferon alpha; DM, diabetes mellitus; RA, rheumatoid arthritis; D, discontinuation pegylated interferon alpha; S, supportive care; BK, biventricular pacemaker; N/A, data not available.

^a The IFN- α dose is 6 MU daily for the first 2 weeks and 6 MU 3 times weekly thereafter.

The present patient was the first case to develop cardiomyopathy and hypothyroidism after standard of care antiviral treatment for HCV infection. In this case, Peg IFN- α may have been responsible for the onset of cardiomyopathy. Arguments in support of a correlation between Peg IFN- α and cardiomyopathy include the following aspects: all other possible infectious and drugs or systemic causes were ruled out; cardiotoxicity was present during Peg IFN- α treatment; cardiotoxicity regression after drug withdrawal; absence of any previous heart disease history and specific investigations before treatment excluding a pre-existing cardiomyopathy, and the symptoms and the results of the various investigations carried out in the context of the dilated cardiomyopathy. We used the causal criteria from the World Health Organization to show the probability of adverse drug reaction.¹⁴

The mechanism behind IFN- α induced cardiotoxicity was not yet clarified. In reported cases, the dose of standard IFN- α was always higher than three million units, three times a week, and in the majority of cases very high doses were used.^{7,8,10,11} Cardiomyopathy associated with standard IFN- α treatment for CHC is extremely rare, maybe due to the lower doses. The only two reported cases were administration of IFN- α at a dose of six million units daily for the first two weeks and six million units three times weekly thereafter.⁸ Our patient present cardiomyopathy during Peg IFN- α rather than standard IFN- α therapy. Whatever the mechanism, it is conceivable that pegylated interferon provides higher levels of interferon plasma concentration in a continuous fashion because of prolonged half-life, and thus could bear a higher risk of cardiomyopathy. On the other hand, there are no described predisposing factors for interferon cardiotoxicity. Studies have shown that combination therapy with Peg IFN- α and ribavirin does not cause a significant deterioration in cardiac function in patients without cardiac disease¹⁵ and may be safely offered to carefully selected chronic hepatitis C patients with coexisting, clinically significant heart disease,¹⁶ indicating that the diverse genetic predisposition of the individuals may substantially contribute to cardiotoxicity.

Cardiomyopathy induced by standard IFN- α was always reversible when there was no concomitant factor.^{7,8,11} Conversely, Peg IFN- α related cardiomyopathy showed a poor prognosis.^{12,13} Although our case had complete resolution of the cardiomyopathy, one case died due to cardiogenic shock¹² and another case had irreversible ventricular dysfunction and

remains symptomatic despite maximal medical therapy and implant of a biventricular pacemaker.¹³

TD is a relatively common adverse reaction to IFN- α based therapy and it also represents an extra-hepatic manifestation of HCV infection.^{3,5} Studies have shown that the incidence of TD associated with IFN- α therapy differs markedly between racial and ethnic groups and fibrosis stages, with an incidence ranging from 10% to 27.7%.²⁻⁶ The majority of TD is hypothyroidism, and more than half of them return spontaneously to normal after cessation of antiviral therapy.³⁻⁶ However, a few patients, as well as our case, need permanent thyroid hormone replacement therapy.³⁻⁶ Fortunately, it does not always necessitate alteration or discontinuation of therapy due to TD,^{2-6,17} and it also does not impact the response to combination therapy with interferon and ribavirin.^{3,17}

Conclusion

We report a patient without any history of cardiac disease who developed dilated cardiomyopathy and hypothyroidism after Peg IFN- α plus ribavirin treatment. Cardiomyopathy is an exceptional but unanticipated complication of antiviral therapy for HCV infection. It may be associated with the diverse genetic predisposition of individuals. Prompt discontinuation of HCV medication is mandatory, and short-term heart failure medications together with supportive care are essential. Clinicians should be aware of this potentially cardiovascular complication and the possible acuity of its onset. We suggest that periodic monitoring of the cardiac function is necessary, especially for symptomatic patients, to detect early toxic effects during interferon administration.

Financial support

This work was supported by Personnel training special funds of the Second Affiliated Hospital, College of Medicine, Xi'an Jiaotong University [RC(XM)201105] and The Health Research Foundation of Shaanxi Province (No. 2010H31).

Conflicts of interest

The authors declare no conflicts of interest.

Acknowledgements

This work was supported by Personnel training special funds of the Second Affiliated Hospital, College of Medicine, Xi'an Jiaotong University [RC(XM)201105] and The Health Research Foundation of Shaanxi Province (No. 2010H31).

REFERENCES

- Lauer GM, Walker BD. Hepatitis C virus infection. *N Engl J Med.* 2001;345:41-52.
- Andrade LJ, Atta AM, Atta ML, Mangabeira CN, Parana R. Thyroid disorders in patients with chronic hepatitis C using interferon alpha and ribavirin therapy. *Braz J Infect Dis.* 2011;15:377-81.
- Yan Z, Fan K, Fan Y, et al. Thyroid dysfunction in Chinese patients with chronic hepatitis C treated with interferon alpha: incidence, long-term outcome and predictive factors. *Hepat Mon.* 2012;12:e6390.
- Gelu-Simeon M, Burlaud A, Young J, Pelletier G, Buffet C. Evolution and predictive factors of thyroid disorder due to interferon alpha in the treatment of hepatitis C. *World J Gastroenterol.* 2009;15:328-33.
- Rodríguez-Torres M, Ríos-Bedoya CF, Ortiz-Lasanta G, Marxuach-Cuétara AM, Jiménez-Rivera J. Thyroid dysfunction (TD) among chronic hepatitis C patients with mild and severe hepatic fibrosis. *Ann Hepatol.* 2008;7:72-7.
- Pavan MH, Pavin EJ, Gonçalves Jr FL, Wittmann DE. Virus C genotype predisposes to primary hypothyroidism during interferon-alpha treatment for chronic hepatitis C. *Braz J Infect Dis.* 2011;15:449-56.
- Sonnenblick M, Rosin A. Cardiotoxicity of interferon. A review of 44 cases. *Chest.* 1991;99:557-61.
- Teragawa H, Hondo T, Amano H, Hino F, Ohbayashi M. Adverse effects of interferon on the cardiovascular system in patients with chronic hepatitis C. *Jpn Heart J.* 1996;37:905-15.
- Popescu C, Arama V, Gliga S. Acute pericarditis due to pegylated interferon alpha therapy for chronic HCV hepatitis - case report. *BMC Gastroenterol.* 2011;11:30.
- Rauw J, Ahmed S, Petrella T. Pericardial effusion and tamponade following interferon alpha treatment for locally advanced melanoma. *Med Oncol.* 2012;29:1304-7.
- Cohen MC, Huberman MS, Nesto RW. Recombinant alpha 2 interferon-related cardiomyopathy. *Am J Med.* 1988;85:549-51.
- Condat B, Asselah T, Zanditenas D, et al. Fatal cardiomyopathy associated with pegylated interferon/ribavirin in a patient with chronic hepatitis C. *Eur J Gastroenterol Hepatol.* 2006;18:287-9.
- Choy-Shan A, Berezovskaya S, Zinn A, Sedlis SP, Bini EJ. Nonischemic cardiomyopathy related to pegylated interferon and ribavirin. *Eur J Gastroenterol Hepatol.* 2009;21:1438-40.
- Edwards IR, Aronson JK. Adverse drug reactions: definitions, diagnosis, and management. *Lancet.* 2000;356:1255-9.
- Almawardy R, Elhammady W, Mousa N, Abotaleb Sh. Is combination therapy for chronic hepatitis C toxic for cardiac function? *Hepat Mon.* 2012;12:e6254.
- Durante-Mangoni E, Iossa D, Pinto D, De Vincentiis L, Ragone E, Utili R. Safety and efficacy of peginterferon alpha plus ribavirin in patients with chronic hepatitis C and coexisting heart disease. *Dig Liver Dis.* 2011;43:411-5.
- Barut S, Gunal O, Erkorkmaz U, Yildiz F. Thyroid dysfunction in Turkish patients with chronic hepatitis C receiving peginterferon plus ribavirin in the period of 2005-2010. *Braz J Infect Dis.* 2012;16:448-51.