



The Brazilian Journal of INFECTIOUS DISEASES

www.elsevier.com/locate/bjid



Clinical image

“Catarrhal physiognomy” and Koplik’s spots

Zhengxiao Li^a, Wenxue Zhao^b, Fanpu Ji^{b,*}

^a Department of Dermatology and Venereology, The Second Affiliated Hospital, College of Medicine, Xi’an Jiaotong University, China

^b Department of Infectious Diseases, The Second Affiliated Hospital, College of Medicine, Xi’an Jiaotong University, China

ARTICLE INFO

Article history:

Received 13 November 2012

Accepted 24 November 2012

Available online 9 May 2013

A 22-year-old female presented with a 5-day history of fever, conjunctivitis, coryza, cough, nasal discharge and 1-day of dyspnea. A maculopapular rash had appeared on her face two days ago and had spread to her upper torso and shoulders. The patient had never been vaccinated against measles. On examination, the temperature was 39.1 °C, with a pulse rate of 103 and a respiratory rate of 23 breaths per minute. Physical examination showed notable exudate around eyes, alae nasi and oral lips (Fig. 1A) and small white spots on the buccal mucosa that resembled grains of salt and had a reddish background (Fig. 1B, arrow). We identified them as “catarrhal physiognomy” and Koplik’s spots and diagnosed measles. The diagnosis was later confirmed by the presence of anti-measles IgM antibodies. The dyspnea was due to a mild form of measles bronchopneumonia. The patient with supportive care recovered uneventfully.

Measles is a highly contagious disease caused by measles virus and was one of the most devastating infectious diseases

of human before the introduction of the measles vaccines.¹ Koplik’s spots are highly characteristic of the prodromal phase of measles and can often be identified before the onset of the rash, which had been originally described in 1896.² Koplik’s spots are classically present on the buccal mucosa opposite the second molars early in the course of measles, occasionally extending to the whole buccal mucosa.^{2,3} Koplik’s spots can be noted in at least 50–70% of patients, and have been regarded as pathognomonic features of measles.^{1–3} Recent study demonstrates that Koplik’s spots were highly predictive of confirmed measles and could be a timely tool to enable prompt management and control measures prior to laboratory confirmation.⁴ “Catarrhal physiognomy” can be noted in severe cases before onset of the rash in the prodromal phase of measles. The recognition of “catarrhal physiognomy” and Koplik’s spots can lead to early diagnosis of measles and then limit transmission of the virus.

* Corresponding author at: Department of Infectious Diseases, The Second Affiliated Hospital, College of Medicine, Xi’an Jiaotong University, 157 Xi Wu Road, Xi’an 710004, Shaanxi Province, China.

E-mail address: jifanpu1979@163.com (F. Ji).

1413-8670 © 2013 Elsevier Editora Ltda. Este é um artigo Open Access sob a licença de CC BY-NC-ND
<http://dx.doi.org/10.1016/j.bjid.2012.11.004>

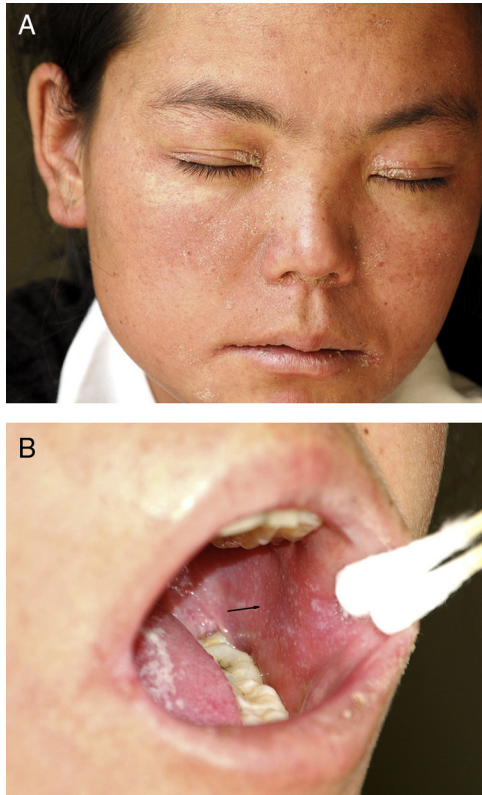


Fig. 1 - (A) Notable exudate around eyes, alae nasi and oral lips and (B) small white spots on the buccal mucosa that resembled grains of salt and had a reddish background.

Conflict of interest

All authors declare to have no conflict of interest.

REFERENCES

1. Moss WJ, Griffin DE. Measles. *Lancet*. 2012;379:153-64.
2. Koplik H. The diagnosis of the invasion of measles from a study of the exanthema as it appears on the buccal mucous membrane. *Arch Pediatr*. 1896;13:918-22.
3. Steichen O, Dautheville S. Koplik spots in early measles. *Can Med Assoc J*. 2009;180:583.
4. Zenner D, Nacul L. Predictive power of Koplik's spots for the diagnosis of measles. *J Infect Dev Ctries*. 2012;6:271-5.